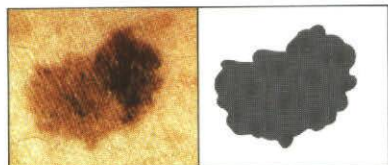


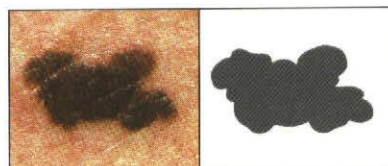


**LOOK FOR
DANGER SIGNS
IN PIGMENTED LESIONS
OF THE SKIN**

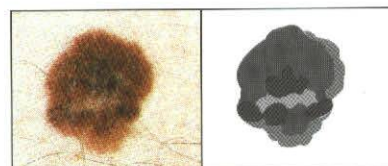
Consult your dermatologist **immediately** if any of your moles or pigmented spots exhibit:



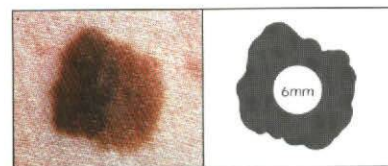
A **Asymmetry**-one half unlike the other half.



B **Border irregular**-scalloped or poorly circumscribed border.



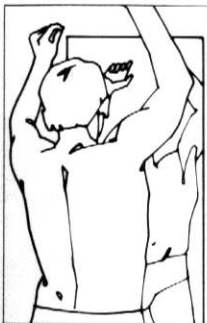C **Color varied** from one area to another; shades of tan and brown; black; sometimes white, red or blue.



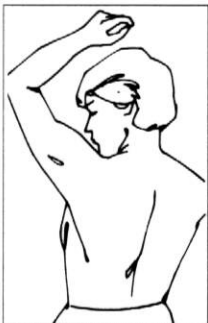D **Diameter larger** than 6mm as a rule (diameter of pencil eraser).

MIND THESE ABCD's
They may be signs of malignant melanoma.

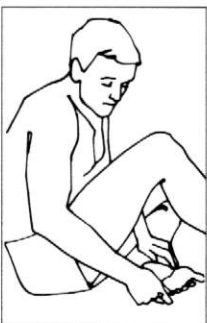-over-



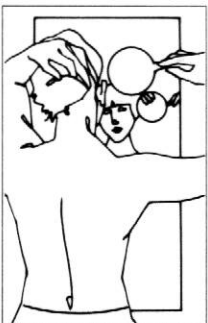1 Examine your body front and back in the mirror, then right and left sides arms raised.



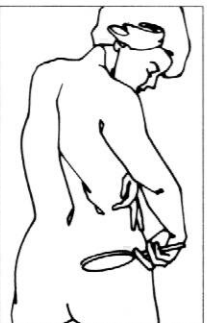
2 Bend elbows and look carefully at forearms and upper arms and palms.



3 Look at the backs of the legs and feet — spaces between toes, and sole.



4 Examine backs of neck and scalp with a hand mirror. Part hair for a closer look.



5 Finally, check back and buttocks with hand mirror.

Self-Examination for Melanoma

Practice Frequent Self-Examinations.

Remember! Prompt surgical excision of an early melanoma offers an excellent chance of a cure. If you have any doubt about a mole, see a dermatologist.

© 1993
American Academy of Dermatology
P.O. Box 4014
Schaumburg, IL 60168-4014



BKMK86-9/93